


# NSTEMI in the Setting of Microangiopathic Hemolytic Anemia: A Rare Complication of a Rare Disease Process



Hunter Rhodes, Mohammad Khattab, Isma Javed, Sardar Ijaz, Lyndsey Jones, Karen Beckman M.D  
University of Oklahoma Health Sciences Center, Oklahoma City, OK

## BACKGROUND

- ❖ Microangiopathic hemolytic anemia (MAHA) is usually caused by infection, autoimmune disorders, and/or genetic predisposition.
- ❖ More recently MAHA secondary to cocaine use has been described. We report a case of cocaine-induced MAHA presenting as non-ST elevation myocardial infarction (NSTEMI).

## CASE PRESENTATION

- ❖ **Presentation:** A 44-year-old male with hypertension, ankylosing spondylitis and cocaine abuse presented with new onset of chest pain.
- ❖ **Evaluation:** Electrocardiography revealed mild ST elevation (did not meet criteria for STEMI) and a troponin of 5 ng/ml.
- ❖ **Echocardiography (TTE)** showed regional wall motion abnormalities (RWMA) and mildly depressed ejection fraction (EF). Urgent coronary angiography showed high-grade stenosis of the left circumflex artery.
- ❖ **Diagnosis :** After coronary angiography but before intervention his admission labs returned revealing: hemoglobin 7.1 gm/dl, platelets 46,000/mm<sup>3</sup>, serum creatinine 7.63 mg/dl. Urine drug screen was positive for cocaine. MAHA was diagnosed after further workup revealed hemolysis.
- ❖ **Clinical Decision Making:**
  - Given the RWMAs and newly reduced EF, urgent revascularization seemed appropriate.
  - Urgent coronary angiography showed high grade stenosis of the left circumflex artery.
  - The presence of severe anemia and thrombocytopenia (increased bleeding risk) and the positive urine cocaine (increased risk of noncompliance with dual antiplatelet therapy) informed the decision to implant a bare-metal instead of a drug-eluting stent.
  - A bare-metal stent was placed in the left circumflex artery.

## IMAGES

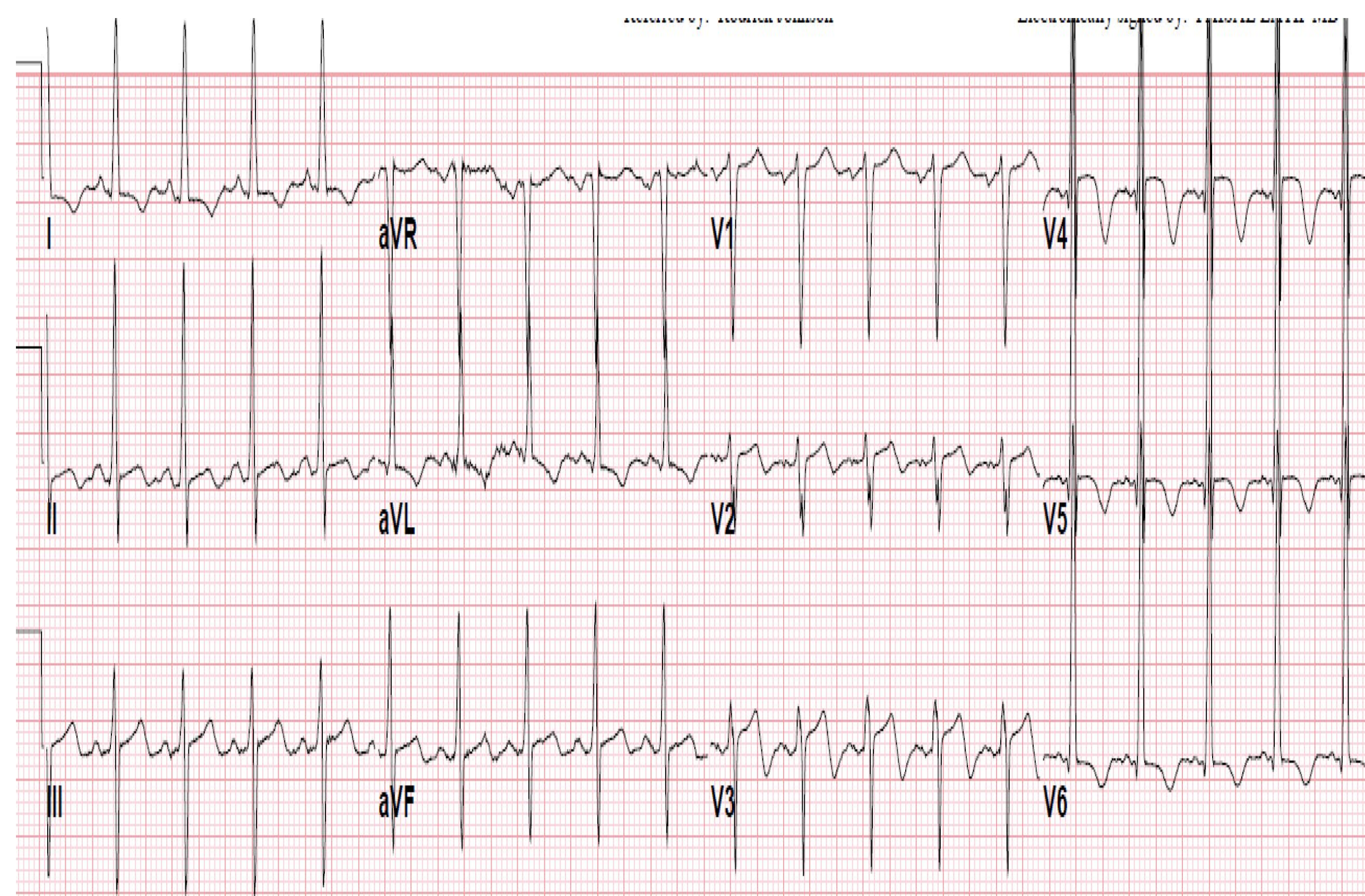


Figure 1: Electrocardiography with mild ST elevation (does not meet STEMI criteria) and reciprocal changes.

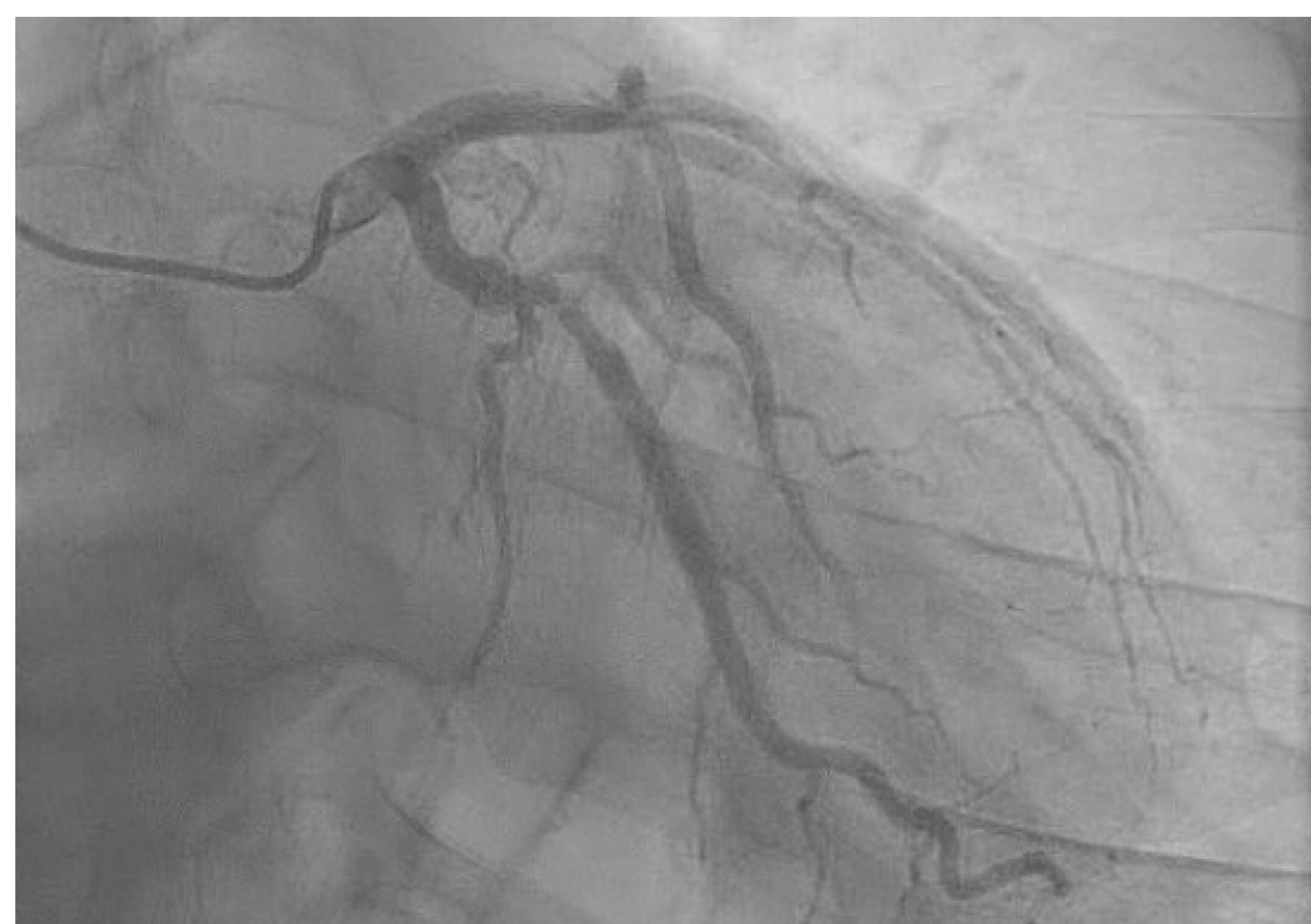

Figure 2: Coronary Angiography with high grade Left circumflex stenosis.

## DISCUSSION

- ❖ ACC/AHA NSTEMI guidelines advise immediate invasive strategy in patients with certain high-risk features. In the absence of refractory or recurrent angina, heart failure, or arrhythmias we debated the need for immediate revascularization.
- ❖ Given the high-risk nature of his MI including ST elevations (although not STEMI criteria) with reciprocal changes, newly mildly reduced ejection fraction (prior TTE was normal), it was likely that this patient was an ideal candidate for revascularization at that time.
- ❖ Cocaine results in vasoconstriction, endothelial injury, enhanced platelet activity, and procoagulation. Endothelial injury induces fibrin deposition and platelet aggregation leading to MAHA.
- ❖ Cocaine-induced MAHA is likely under-diagnosed because it is rare and drug testing is not often performed.. Clinicians need to have a high level of suspicion for possible cocaine-induced MAHA in cocaine-users who present similarly to patients with TTP.

## CONCLUSION

- ❖ MAHA is a rare complication of cocaine use and complicates the treatment of cocaine-induced infarct.
- ❖ This case highlights a rare scenario with interesting pathophysiologic considerations when deciding between an immediate versus early invasive or ischemia-guided strategy for the management of NSTEMI in the setting of noncardiac co-morbidities.

## REFERENCES

1. Odronic S, Quraishy N, Manroa P, Kier Y, Koo A, Figueroa P, et al. Cocaine-induced microangiopathic hemolytic anemia mimicking idiopathic thrombotic thrombocytopenic purpura: a case report and review of the literature. *J Clin Apher.* 2014;29(5):284-9.
2. Gu X, Herrera GA. Thrombotic microangiopathy in cocaine abuse-associated malignant hypertension: report of 2 cases with review of the literature. *Arch Pathol Lab Med.* 2007;131(12):1817-20.

**Disclosure:** No Financial disclosure