

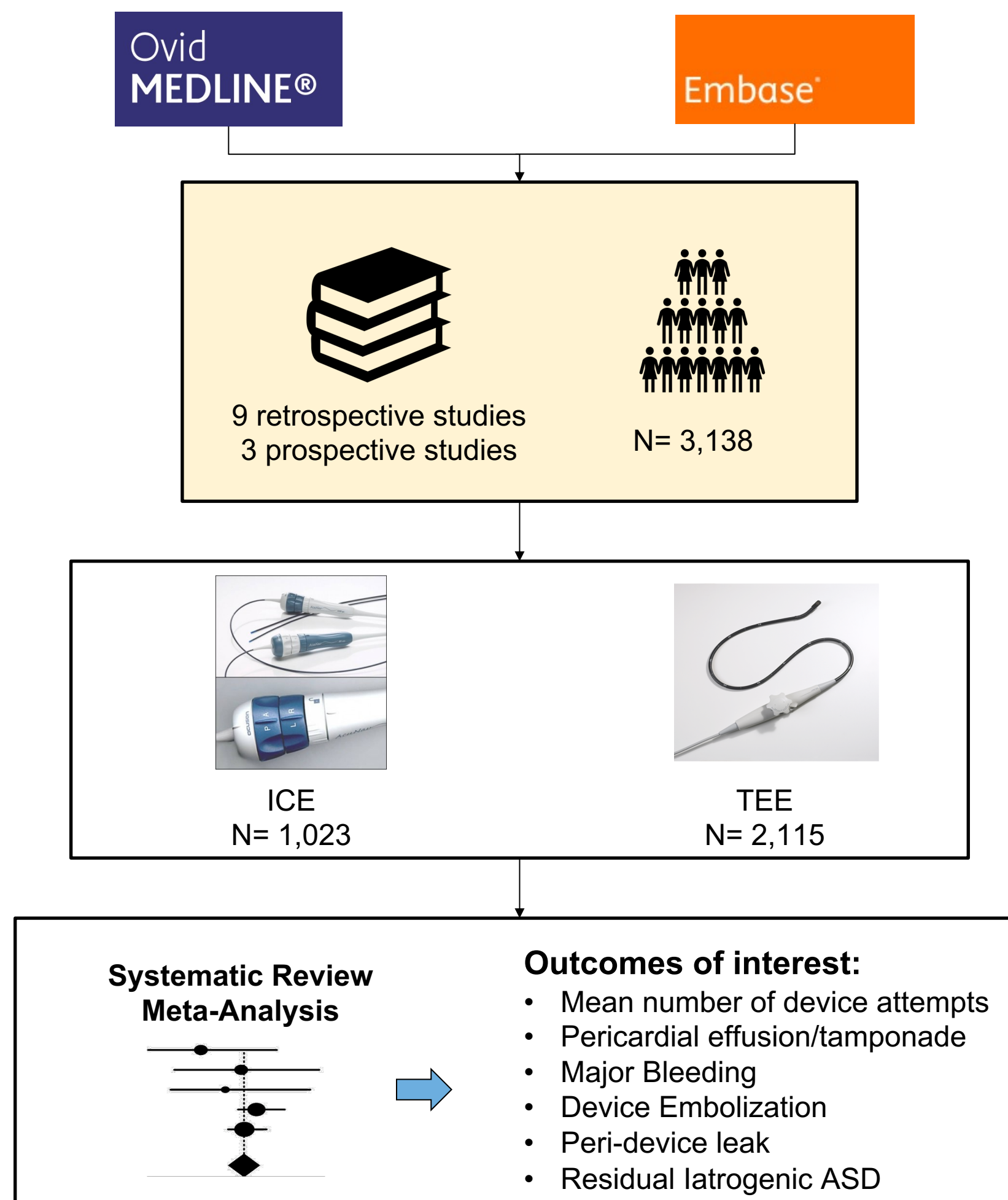
Comparison of Intracardiac Echocardiography with Transesophageal Echocardiography for Left Atrial Appendage Occlusion: An Updated Systematic Review and Meta-Analysis

Satyam Krishan, MD; Laila Hashim, MD; Laraib Javed, MD; Janeth Gomez-Perez, MD; Mohammad Khattab, MD; Jehanzeb Khan, MD, Rohaan Muhammad, DO, Jalal Gondal, MD, John Walker Sacco, MD, Canisia Tatah, MD, Shazmah Shahrukh, MBBS, Fiza Farrukh, MBBS, Shari Clifton, MLIS; Bilal Munir, MD; Christopher DeSimone, MD; Abhishek Deshmukh, MD; Zain Ul Abideen Asad MD


BACKGROUND

Use of Intracardiac Echocardiography (ICE) to guide implantation of Left Atrial Appendage Occlusion (LAAO) devices is a novel and emerging approach. Data comparing ICE vs Transesophageal Echocardiography (TEE) as an intra-procedural imaging modality in this setting is lacking. We hypothesized that use of ICE would be associated with similar or improved clinical outcomes compared to TEE during LAAO.

METHODS



Left Atrial Appendage Occlusion with Intracardiac Echocardiography is associated with Higher Odds of Iatrogenic Atrial Septal Defect but Lower Mean Number of Device Attempts.



Scan the QR code and follow us on twitter!
@SatyamKrishan1
@ZainAsadEP

Email:
Satyam-Krishan@ouhsc.edu

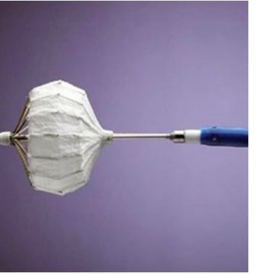
ACC.23
TOGETHER WITH
WCC

RESULTS

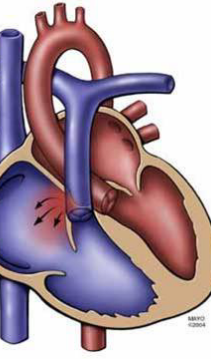
Left Atrial Appendage Occlusion with Intracardiac Echocardiography is associated with:



Mean Device Attempts
(SMD -0.24 [95% CI -0.43, -0.04]; p=0.02)



Iatrogenic Atrial Septal Defect
(OR 1.92 [95% CI 1.37, 2.7] p=0.0002)



No difference was observed in:

Major Vascular Complications
(OR 1.16 [95% CI 0.51, 2.64]; p=0.72)

Major Bleeding
(OR 0.6 [95% CI 0.34, 1.06]; p=0.08)

Peri-Device Leak
(OR 0.96 [95% CI 0.72, 1.3]; p=0.81)

DISCLOSURE INFORMATION

The authors have no conflicts of interests or industry relationships to disclose.